

# Magnet-assisted Rigid Bronchoscopy for Removal of a Peripheral Metallic Airway Foreign Body in Pediatrics: A Case Report

## *Broncoscopia rígida asistida con imán para la extracción de un cuerpo extraño metálico periférico en pediatría: Reporte de caso*

Cintia P. Antonioli<sup>1</sup>, Vanina M. Lucero<sup>2</sup>, María Antonella Schab<sup>2</sup>, María José Farina<sup>2</sup>

<sup>1</sup> Pulmonology Service, Hospital de Niños Sor María Ludovica, La Plata, Argentina.

<sup>2</sup> Otorhinolaryngology Service, Hospital de Niños Sor María Ludovica, La Plata, Argentina.

Received: 14/12/2025

Accepted: 09/02/2026

### Correspondence

Cintia Patricia Antonioli.

Correo electrónico:

Email: cin421@hotmail.com.ar

### ABSTRACT

Foreign body aspiration is a frequent pediatric emergency and may be associated with significant morbidity and mortality. The removal of metallic foreign bodies located in peripheral bronchial regions represents a technical challenge, particularly when conventional instruments do not allow adequate access. We report the case of a 7-year-old pediatric patient with aspiration of a metallic foreign body (pin) lodged distally in the right bronchial tree. Due to the inability to visualize and extract the object using standard bronchoscopic techniques, a handmade magnet-assisted device was introduced through a rigid bronchoscope under fluoroscopic guidance. This approach allowed complete removal of the foreign body in a short operative time and without complications. Magnet-assisted rigid bronchoscopy under fluoroscopic guidance represents a safe and effective alternative for the extraction of peripheral metallic foreign bodies in the pediatric airway, especially when conventional instrumentation proves insufficient.

**Key words:** rigid bronchoscopy foreign body pediatrics airway magnet

### RESUMEN

La aspiración de cuerpos extraños en la vía aérea constituye una urgencia frecuente en pediatría y puede asociarse a una elevada morbimortalidad. La extracción de cuerpos extraños metálicos localizados en regiones bronquiales periféricas representa un desafío técnico, especialmente cuando los instrumentos convencionales no permiten un acceso adecuado. Se presenta el caso de una paciente pediátrica de 7 años con aspiración de un

Rev Am Med Resp 2026;26:36-39. <https://doi.org/10.56538/ramr.PWIJ3874>



<https://creativecommons.org/licenses/by-nc-sa/4.0/>

cuerpo extraño metálico (alfiler), localizado distalmente en el árbol bronquial derecho. Ante la imposibilidad de visualización y extracción mediante técnicas broncoscópicas habituales, se utilizó un dispositivo artesanal imantado introducido a través de un broncoscopio rígido bajo guía radioscópica, lo que permitió la extracción completa del objeto en un tiempo operatorio breve y sin complicaciones. La broncoscopia rígida asistida con imán guiada por radioscopia constituye una alternativa segura y eficaz para la extracción de cuerpos extraños metálicos periféricos en la vía aérea pediátrica, especialmente en situaciones en las que el instrumental convencional resulta insuficiente.

**Palabras clave:** broncoscopia rígida cuerpo extraño pediatría vía aérea imán

## INTRODUCTION

Foreign body (FB) aspiration in the pediatric population is a major cause of morbidity and mortality and a common clinical emergency, particularly in children under 5 years. Factors such as immature swallowing mechanisms, absence of molar teeth, age-related oral exploratory behavior, and inappropriate habits such as playing with objects in the mouth contribute to its high incidence.<sup>1,2</sup>

Removal of FBs located in peripheral regions of the lung poses a considerable technical challenge, particularly when small metallic objects are involved. The narrow caliber of the pediatric bronchial tree and the high density of these objects predispose them to distal migration, hindering visualization and retrieval with conventional instruments.<sup>1</sup>

Rigid bronchoscopy has traditionally been considered the procedure of choice for FB extraction in pediatric patients because it provides adequate airway control and ventilation, while allowing the use of larger-caliber instruments. However, flexible bronchoscopy offers the advantage of accessing more distal airways, although its therapeutic utility is limited by the small diameter of the working channel, which in pediatric bronchoscopes may be as narrow as 1.2 mm.<sup>3</sup>

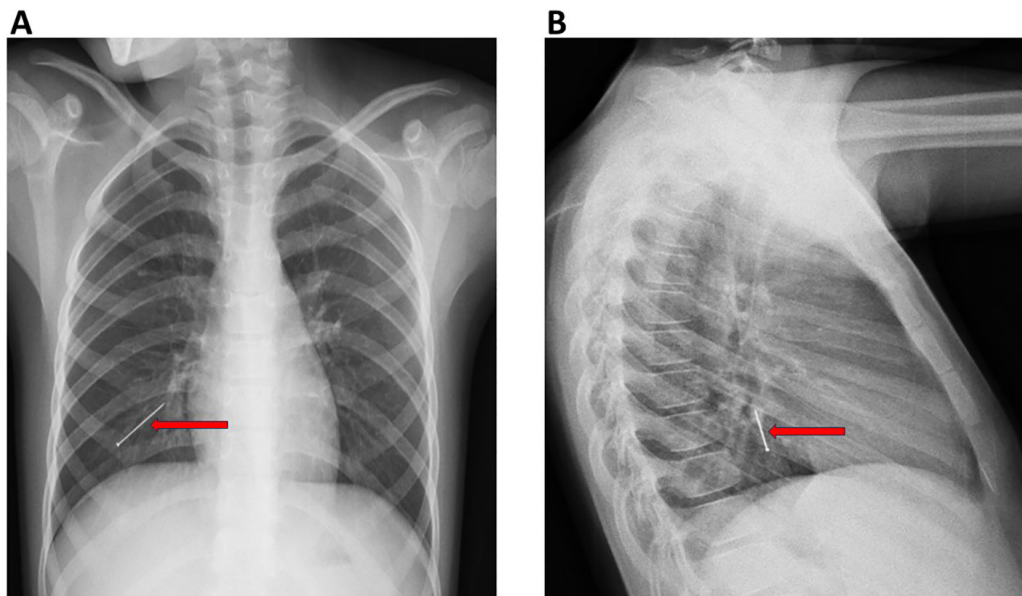
Extracting smooth, metallic FBs that are impacted or have migrated distally beyond the reach of forceps or retrieval baskets, is technically challenging and potentially hazardous.<sup>1</sup> In the absence of commercially available magnet-assisted devices, some centers have developed improvised technical adaptations to facilitate retrieval of these objects.<sup>1,4,5</sup>

The aim of this report is to describe a combined technique using rigid bronchoscopy and magnet-assisted retrieval under fluoroscopic guidance for removal of a metallic foreign body lodged in the peripheral airway of a pediatric patient.

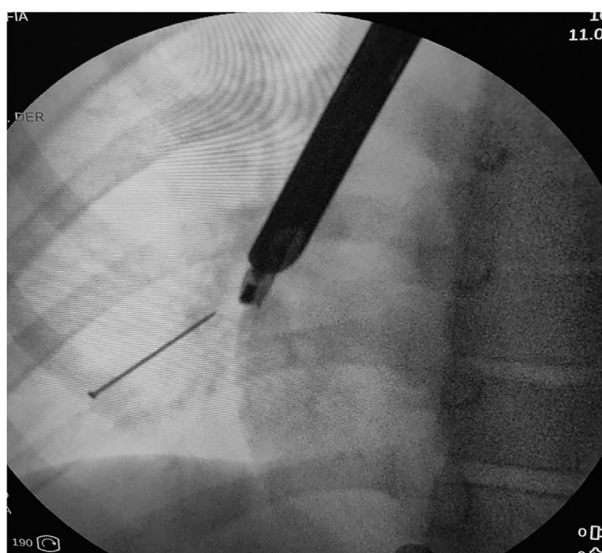
## CASE DESCRIPTION

A 7-year-old girl presented with a history of metallic foreign body aspiration (pin). Imaging studies demonstrated the object lodged within the anterior segment of the right lower lobe (Figure 1). Therapeutic bronchoscopy was indicated. The procedure was performed under general anesthesia. Initial rigid bronchoscopy using a telescope followed by flexible bronchoscopy failed to visualize the FB, which was detectable only under fluoroscopic guidance. Given this situation, a custom-made retrieval device was assembled to facilitate extraction. The device consisted of a suction cannula with a magnet secured to its distal tip with adhesive tape. This design was intended to attract and mobilize the foreign body into a more proximal bronchial segment or achieve complete extraction. The device was firmly secured to the instrument to prevent detachment during the procedure. Before clinical use, an ex vivo preprocedural test confirmed device stability under loads exceeding those anticipated during the intervention, with no evidence of detachment. Under fluoroscopic guidance, the magnetized cannula was introduced through the rigid bronchoscope (Figure 2), and complete retrieval of the foreign body was achieved without the need for additional maneuvers or associated complications. Total procedural time, measured from insertion of the rigid bronchoscope to removal of the object, was

**Figure 1.** Chest radiograph. **A.** Anteroposterior projection: A linear metallic foreign body (arrow) is observed projecting over the right hemithorax at the level of the lower third of the lung field. **B.** Lateral projection: The foreign body is localized within the posterior lung field, consistent with a peripheral location in the right lower lobe.



**Figure 2.** Intraoperative fluoroscopic image. A rigid bronchoscope is visualized within the airway. Through the bronchoscope, a suction cannula with a magnet attached to its distal tip can be identified. Inferior to and in direct relation with the magnet, a metallic foreign body consistent with a pin is observed. The spatial arrangement suggests effective magnetic attraction, with alignment of the foreign body toward the distal end of the device.



less than 1 minute. No bronchial mucosal injury or postoperative complications were observed.

Written informed consent for the procedure and publication of the case was obtained from the patient's parents.

## DISCUSSION

Removal of metallic FBs lodged in peripheral regions of the airway remains a challenge in pediatric bronchoscopy. Limitations of conventional instruments, combined with the small bronchial caliber in children, may prolong procedural time and increase the risk of complications. Magnet-assisted rigid bronchoscopy offers an effective, accessible, and low-cost alternative in selected cases. Use of a magnet allows a traumatic mobilization of smooth metallic FBs that would otherwise be difficult to grasp using forceps or retrieval baskets, particularly when they cannot be directly visualized endoscopically.

Although previous reports have described the use of magnet-assisted devices for airway foreign body retrieval, their application in pediatric patients remains limited.<sup>1,4,5</sup> In the present case, the technique enabled rapid and safe extraction, thereby avoiding more prolonged or invasive procedures. The main limitations of this report include the description of a single case and the use of a custom-made device. Nevertheless, this experience suggests that the technique may be particularly useful in young children, in whom the dimensions of the bronchial tree restrict the use of conventional retrieval maneuvers. Magnet-assisted rigid bronchoscopy under fluoroscopic guidance represents a safe and effective technique

for removal of metallic foreign bodies lodged in peripheral regions of the pediatric airway. Its implementation may reduce operative time and help avoid more invasive procedures in selected cases.

#### Conflict of interest

Authors have no conflicts of interest to declare.

#### Funding

This study received no external funding.

#### Ethical considerations

Written informed consent for publication of the case was obtained from the patient's parents. Because this was a single case report, institutional ethics committee approval was not required.

## REFERENCES

1. Sarafi M, Rouzrokh M, Sadr S, Mahdavi SA, Mahdavi NS, Ebrahimiyan M. The usage of a magnet-powered instrument in the extraction of metallic or magnetic aspirated foreign bodies: a case report. *Int J Surg Case Rep.* 2022;99:107629. <https://doi.org/10.1016/j.ijscr.2022.107629>.
2. Safia A, Abd Elhadi U, Bader R, et al. Flexible versus rigid bronchoscopy for tracheobronchial foreign body removal in children: a comparative systematic review and meta-analysis. *J Clin Med.* 2024;13:5652. <https://doi.org/10.3390/jcm13185652>.
3. Hegde S, Bahadur U, Kanojia RP, Bawa M, Samujh R. Bronchoscopic airway foreign body extraction without using optical forceps. *J Indian Assoc Pediatr Surg.* 2018;23(2):87-89. [https://doi.org/10.4103/jiaps.JIAPS\\_85\\_17](https://doi.org/10.4103/jiaps.JIAPS_85_17).
4. Brkic F, Umihanic Sekib, Altumbabic H, et al. Death as a consequence of foreign body aspiration in children. *Med Arch.* 2018;72:220-3. <https://doi.org/10.5455/medarh.2018.72.220-223>.
5. Elsayed HH, Mostafa AM, Soliman S, El-Bawab HY, Moharramb AA, El-Nori AA. A magnet built on bronchoscopic suction for extraction of tracheobronchial headscarf pins: a novel technique and review of a tertiary centre experience. *Interact Cardiovasc Thorac Surg.* 2016;22:616-20. <https://doi.org/10.1093/icvts/iww007>.