

# Tracheobronchial Amyloidosis in the Context of Systemic Disease

## *Amiloidosis traqueobronquial en contexto de enfermedad sistémica*

Carmona, Alejandro A. ; Carmona, Juan M. ; Abdala, Jorge A. 

Received: 02/13/2023

Accepted: 03/06/2023

### Correspondence

Alejandro A. Carmona. Mail:  
alecarmonab@hotmail.com

### ABSTRACT

Centuries after the detection of amyloid material as extracellular deposits, we find various classifications in the literature. Regarding thoracic involvement, four types are recognized, with the tracheobronchial type being the least common.

We present the case of a 32-year-old male patient with no previous medical record, who sought medical attention due to a 3-year history of dysphonia. A nodular lesion was found in the posterior wall of the trachea. A biopsy was performed through fiberoptic bronchoscopy, and the result indicated the presence of tracheobronchial amyloidosis. Chemotherapy was administered, and the possibility of surgical resection was evaluated basing on treatment response.

Pulmonary amyloidosis associated with systemic amyloidosis typically presents as a diffuse interstitial pattern. Tracheobronchial and nodular parenchymal forms are uncommon and manifest with obstructive symptoms. A definitive diagnosis was achieved through biopsy. There are various therapeutic options available, such as chemotherapy, autologous bone marrow transplantation, and for patients with obstructive symptoms, endoscopic resection and stent placement are recommended.

**Key words:** Amyloidosis; Computed tomography; Treatment

### RESUMEN

Siglos después de la detección de material amiloide como depósitos extracelulares, encontramos en la bibliografía diversas clasificaciones. En cuanto a la afección torácica, se reconocen cuatro tipos; el traqueobronquial es el menos frecuente.

Presentamos el caso de un paciente masculino de 32 años sin antecedentes, que consulta por disfonía de 3 años, al que se le constata una lesión nodular en la pared posterior de la tráquea. Se realiza una biopsia por fibrobroncoscopia, cuyo resultado indica la presencia de amiloidosis traqueobronquial. Se realiza quimioterapia y se valora la realización de una resección quirúrgica según respuesta al tratamiento.

La amiloidosis pulmonar asociada con amiloidosis sistémica generalmente se presenta como un patrón intersticial difuso. Las formas traqueobronquial y parenquimatosa nodular no son frecuentes y se manifiestan con síntomas obstructivos. El diagnóstico definitivo se logra mediante biopsia. Disponemos de diversas opciones terapéuticas, como la quimioterapia, el trasplante autólogo de médula ósea y, para pacientes con síntomas obstructivos, se recomienda la resección endoscópica y colocación de *stent*.

**Palabras clave:** Amiloidosis; Tomografía computada; Tratamiento

## INTRODUCTION

In 1854, Rudolph Virchow coined the term “amyloid” to describe the presence of extracellular deposits of a substance similar to cellulose that reacted to iodine. More than 150 years later, the term “amyloidosis” is used to describe the disease characterized by deposits of protein fibers of amyloid material in the tissues, caused in part by imperfect protein metabolism. This progressive accumulation of material that is insoluble and resistant to proteolytic metabolism causes slow and progressive damage to the affected organs, leading to functional collapse.<sup>1-3</sup>

In the global literature, multiple classifications are described for this disease based on its relationship with a triggering cause, histological types, affected organs, or the type of protein deposited.<sup>3</sup>

Four types of thoracic amyloidosis with different characteristics are recognized and can be identified by computed tomography (CT): tracheobronchial, nodular parenchymal, diffuse parenchymal, and lymphadenopathy.<sup>2</sup>

Tracheobronchial involvement, either isolated or in the context of a systemic disease is an unusual form of presentation, accounting for approximately 1% of benign lesions in the tracheobronchial tree. All of this, together with the limited information available in the global literature, poses a diagnostic challenge for physicians.<sup>4</sup>

We report the case of a patient treated by our team with a diagnosis of symptomatic tracheobronchial amyloidosis in the context of asymptomatic systemic disease.

## CASE REPORT

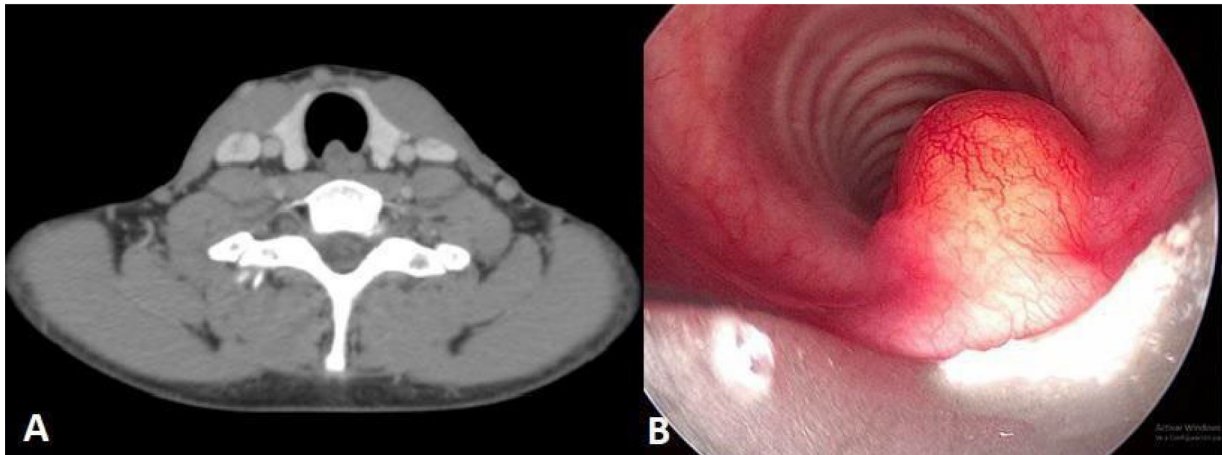
32-year-old male patient. No medical history. The patient presented with a 3-year history of dysphonia without any other associated symptoms. Rhinoscopy and laryngoscopy were performed, revealing a cystic edema-like lesion located in the anterior third of the right ventricle, vocal cord edema, and enlarged and irregular ventricular bands. A computed axial tomography (CAT) showed an 8 mm × 10 mm × 15 mm lesion in the posterior wall of the trachea, at the level of the thyroid. This lesion was nodular, slightly hypodense, of non-specific nature, and didn't change after the administration of intravenous contrast nor during the phonation cycle.

Also, small hypodense images measuring 2.7 mm and 3.7 mm were observed at the free edge of the right inferior vocal cord, and irregular border images were found in the left inferior vocal cord, not exceeding 10 mm in size (Figure 1A). With these results and due to the persistence of the patient's dysphonia, a rigid fiberoptic bronchoscopy (FBC) was performed, revealing a nodular, sessile lesion in the trachea with growth towards the lumen. A biopsy of the described lesion was performed (Figure 1B). The histopathological report revealed laryngeal mucosa without dysplastic changes. There was infiltration of the chorion by a hypocellular, amorphous eosinophilic tissue that exhibited Congo red birefringence under polarized light. Few multinucleated giant cells were present, and there were no signs of vasculitis. These findings are consistent with amyloidosis (Figure 2). It was also decided to perform a biopsy of abdominal adipose tissue and bone marrow to evaluate primary systemic amyloidosis, which yielded a positive result despite the fact that the patient didn't present any signs or symptoms of systemic involvement. The requested laboratory analysis did not show relevant alterations. The cardiac nuclear magnetic resonance didn't show any sign of cardiac amyloidosis. The proposed treatment consisted of chemotherapy cycles with bortezomib in combination with low-dose dexamethasone, along with symptomatic treatment provided by specialists in Speech Therapy and Otorhinolaryngology.

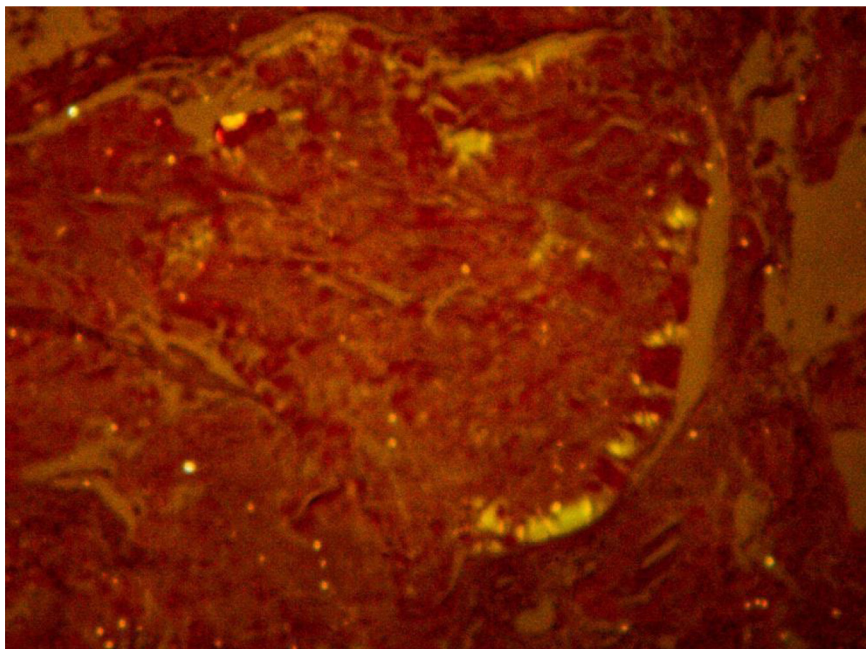
## DISCUSSION

The literature highlights a higher incidence of amyloidosis in male patients over 50 years of age, but respiratory system involvement, particularly in the form of nodules in the tracheobronchial tree, is rare.<sup>1</sup>

There are few published reports on cases of localized primary tracheobronchial amyloidosis, and few authors have described cases of systemic amyloidosis including thoracic involvement in the form of nodules in the airway and respiratory symptoms exclusively.<sup>5</sup> The presented case aligns with the predominant gender, but corresponds to a much younger age range than the one typical for the diagnosis of this disease. It is noteworthy that the onset of symptoms and disease appearance correspond to pulmonary involvement, and the



**Figure 1.** A: Axial slice of intravenous iodinated contrast-enhanced computed tomography, showing the described tracheal lesion. B: Rigid fiberoptic bronchoscopy revealing a subglottic nodular lesion in the posterior side of the trachea.



**Figure 2.** Biopsy of the tracheal lesion with Congo red staining in polarized light, showing apple-green birefringence, indicating extracellular deposits of amyloid material.

systemic involvement in the absence of symptoms of other systems is a finding of interest.

In a retrospective study conducted at Mayo Clinic evaluating patients with pulmonary amyloidosis treated at their center over a period of 13 years, it was concluded that out of the 55 included patients 35 had primary systemic amyloidosis with pulmonary involvement, 17 had localized pulmonary amyloidosis, and 3 had secondary familial amyloidosis. They established that pulmonary

amyloidosis associated with primary systemic amyloidosis generally presents as a diffuse interstitial pattern with or without pleural effusion.<sup>6</sup>

Another more recent study from Mayo Clinic states that patients with localized pulmonary amyloidosis generally don't show evidence of systemic amyloidosis and only have isolated involvement of the parenchyma or the tracheobronchial system.<sup>7</sup> This highlights the uniqueness of the case treated by the authors, where, in the absence of any patho-

logical history, the patient presented with mild upper airway symptoms, without involvement of the pulmonary interstitium or pleura, and only a nodular formation was found in the posterior wall of the trachea, which tested positive for amyloidosis on biopsy. The patient was thoroughly studied, and a positive result for amyloidosis was obtained from a biopsy of adipose tissue.

Isolated tracheobronchial amyloidosis has a variable presentation, ranging from asymptomatic to common symptoms, including dysphonia, stridor, dyspnea, cough, hemoptysis, and dysphagia, with significant morbidity and mortality due to obstructive phenomena. It has subacute presentation and typically begins with progressive dyspnea, wheezing, cough, pneumonia, and episodes of hemoptysis. In cases of tracheobronchial and nodular parenchymal forms, the symptoms generally depend on the segment of the respiratory tree that is affected. Patients with proximal airway involvement predominantly experience obstructive symptoms. On the contrary, those with lesions in the middle airway will experience more symptoms derived from lobar collapse and recurrent infections, while cases where the distal airway is affected may show a history of recurrent pneumonia and bronchiectasis.<sup>6, 8</sup> It is important to highlight the fact that the only symptom of the patient that was treated by the attending team, which led him to seek medical attention, was a 3-year history of dysphonia without any other associated symptoms, which is uncommon according to the literature consulted.

Many cases are initially diagnosed as bronchial asthma, leading to the prescription of incorrect treatments. When symptoms persist, further investigation is necessary to achieve the diagnosis of respiratory amyloidosis.<sup>9</sup> While a definitive diagnosis is made through the histopathological result of a biopsy stained with Congo red under polarized light, the chest CAT scan and FBC are effective complementary tests with high sensitivity and specificity for tracheobronchial amyloidosis.<sup>10</sup> In the present case, the diagnosis was achieved through CAT scan and biopsy performed through FBC.

A multicenter German study, which represents the largest cohort in the literature, investigated the use of chest CAT scans in patients with various presentations of respiratory amyloidosis. The study describes the different findings that can

be observed in these patients and the significant differences between those with tracheobronchial amyloidosis and those with parenchymal variants, either the nodular or the diffuse type. In the first circumferential thickenings, with a reduction in the tracheal lumen, localized wall thickening, and tracheal calcifications were found.<sup>11</sup>

Currently, there is a wide range of therapeutic options available for systemic amyloidosis. One option is conventional chemotherapy with low doses of dexamethasone or its combination with melphalan. Favorable results have also been reported with the combination of proteasome inhibitors, such as bortezomib, in therapy cycles like CYBORD (cyclophosphamide, bortezomib, dexamethasone). This, combined with an autologous bone marrow transplantation, has achieved disease control in over 65% of patients. The use of iodinated anthracycline drugs, such as doxorubicin, has yielded favorable results as it binds to amyloid protein fibers, promoting their degradation.<sup>12</sup>

Regarding the treatment of amyloid deposits in the tracheobronchial tree in the form of tumor-like growth with involvement of the airway lumen, the therapeutic approach will depend on the severity of the patient's respiratory symptoms. Good initial results are described with pharmacological treatment or external beam radiation therapy in patients with mild signs and symptoms, achieving symptom control within a month and up to five years, as described by Neben-Wittich from Mayo Clinic in their published case report. For patients experiencing symptom progression due to mass growth or initially presenting with symptoms that impair their quality of life, endoscopic laser resection is recommended. A thoracic surgery team in Naples, Italy, has published a case in which a patient underwent endoscopic laser photoresection of a mass that compromised 80% of the tracheal lumen and left bronchus. Subsequently, a self-expandable stent was placed to preserve airway permeability in the event of recurrence or scar-related airway stenosis.<sup>13-15</sup> Considering that the patient had mild symptoms without progression in recent years and no impact on quality of life, taking into account that the tracheobronchial involvement is associated with systemic amyloidosis, a decision was made to initiate chemotherapy with bortezomib and dexamethasone. The patient also received phoniatric therapy from the Speech Therapy and Otorhinolaryngology Department and



underwent regular follow-up evaluations together with symptom evaluation and blood count test to assess treatment response. Autologous bone marrow transplantation was to be considered in case of therapeutic failure. 15 months after diagnosis the patient was asymptomatic, in good clinical condition, and showed good treatment response.

#### Conflict of interest

Authors have no conflict of interest to declare.

## REFERENCES

1. Medina Castillo DE, Quiroz Mejía R, Caliope Carrera E, et al. Amiloidosis sistémica. *Dermatol Rev Mex*. 2015;208-18.
2. Aylwin AC, Gishen P, Copley SJ. Imaging appearance of thoracic amyloidosis. *J Thorac Imaging*. 2005;20:41-6. <https://doi.org/10.1097/01.rti.0000154074.29194.09>
3. Lado Lado FL, Ferreiro Regueiro MJ, Cabana Gonzalez B, Diez Diez V, Maceda Vilariño S, Antunez Lopez JR. Amiloidosis. *Medicina Integral*. 2000;36.
4. Peng X, Wang X, Luo D, Zuo W, Yao H, Zhang W. Atypical primary pulmonary amyloidosis: A rare case report. *Medicine (Baltimore)*. 2020;99:e20828. <https://doi.org/10.1097/MD.00000000000020828>
5. Piazza C, Cavaliere S, Foccoli P, Toninelli C, Bolzoni A, Peretti G. Endoscopic management of laryngo-tracheobronchial amyloidosis: a series of 32 patients. *Eur Arch Otorhinolaryngol*. 2003;260:349-54. <https://doi.org/10.1007/s00405-003-0592-0>
6. Utz JP, Swensen SJ, Gertz MA. Pulmonary amyloidosis. The Mayo Clinic experience from 1980 to 1993. *Ann Intern Med*. 1996;124:407-13. <https://doi.org/10.7326/0003-4819-124-4-199602150-00004>
7. Capizzi SA, Betancourt E, Prakash UB. Tracheobronchial amyloidosis. *Mayo Clin Proc*. 2000;75:1148-52. <https://doi.org/10.4065/75.11.1148>
8. Birkeland AC, McHugh JB, Spector ME. Tracheobronchial amyloidosis: A case report and review of the literature. *J Case Rep Med*. 2014;3:235859. <https://doi.org/10.4303/jcrm/235859>
9. Milani P, Basset M, Russo F, Foli A, Palladini G, Merlini G. The lung in amyloidosis. *Eur Respir Rev*. 2017;26:170046. <https://doi.org/10.1183/16000617.0046-2017>
10. Tanriverdi E, Özgül MA, Uzun O, et al. Tracheobronchial Amyloidosis Mimicking Tracheal Tumor. *Case Rep Med*. 2016;2016:1084063. <https://doi.org/10.1155/2016/1084063>
11. Brandelik SC, Heussel CP, Kauczor HU, et al. CT features in amyloidosis of the respiratory system - Comprehensive analysis in a tertiary referral center cohort. *Eur J Radiol*. 2020;129:109123. <https://doi.org/10.1016/j.ejrad.2020.109123>
12. Ryšavá R. AL amyloidosis: advances in diagnostics and treatment. *Nephrol Dial Transplant*. 2019;34:1460-6. <https://doi.org/10.1093/ndt/gfy291>
13. Sommer P, Kumar G, Lipchik RJ, Patel JJ. Tracheobronchial amyloidosis managed with multimodality therapies. *Ther Adv Respir Dis*. 2014;8:48-52. <https://doi.org/10.1177/1753465814524470>
14. Fiorelli A, Accardo M, Galluccio G, Santini M. Amiloidosis traqueobronquial tratada con resección con láser endobronquial y prótesis en Y autoexpansible. *Arch Bronc*. 2013;49:303-5. <https://doi.org/10.1016/j.arbres.2012.11.013>
15. Dahl KA, Kernstine KH, Vannatta TL, Karwal MW, Thomas KW, Schraith DF. Tracheobronchial amyloidosis: a surgical disease with long-term consequences. *J Thorac Cardiovasc Surg*. 2004;128:789-92. <https://doi.org/10.1016/j.jtcvs.2004.03.036>