

Epidemiological and Radiological Characteristics of a Group of Patients with Tuberculous Pneumonia without Immunosuppression or Comorbidities

Características epidemiológicas y radiológicas en un grupo de pacientes con neumonía tuberculosa sin inmunodepresión o comorbilidades

Ortega, Mayra[✉]; Gallego, Claudio[✉]; Poropat Alejandra[✉]; Salomone, César[✉]

Received: 07/29/2022

Accepted: 11/07/2022

Correspondence

Mayra Ortega:
mayra_ortega92@hotmail.com

ABSTRACT

Tuberculous pneumonia is a rare disease, mostly described in patients with immunosuppression or comorbidities such as alcoholism or diabetes, with a radiological presentation similar to bacterial pneumonia, which can lead to diagnostic delays. This study includes patients diagnosed with tuberculosis and with a radiological image of consolidation in lower lung fields, without associated comorbidities. Over the course of 3 years, we identified 25 patients with these criteria among 628 evaluated cases of pulmonary tuberculosis. We didn't find any relationship with sex; and the right lower lobe was more frequently affected (84%) than the left.

Key words: Tuberculosis; Tuberculous pneumonia; Pneumonia

RESUMEN

La neumonía tuberculosa es una patología poco frecuente, descrita mayormente en pacientes con inmunosupresión o comorbilidades como alcoholismo o diabetes, con una presentación radiológica similar a la neumonía bacteriana lo cual puede dar lugar a retrasos en el diagnóstico. En este trabajo se incluyeron pacientes con diagnóstico de tuberculosis e imagen radiológica de consolidación en los campos pulmonares inferiores y sin comorbilidades asociadas. En el transcurso de 3 años identificamos 25 pacientes con estos criterios entre 628 casos de tuberculosis pulmonar evaluados. No encontramos relación con el sexo, resultando más frecuente la afectación del lóbulo inferior derecho (84%) que el izquierdo.

Palabras clave: Tuberculosis; Neumonía tuberculosa; Neumonía

INTRODUCTION

Tuberculosis is a public health issue, caused by *Mycobacterium tuberculosis*. The World Health Organization has been publishing reports since 1997 with the purpose of putting an end to tuberculosis (TB) on a worldwide level.^{1,2} The “End TB” strategy proposes reducing the number of deaths by 95%, and the incidence by 90%, in order to achieve less than 10/100,000 inhabitants in the 2015-2035 period.³ The Covid-19 pandemic threatens the established programs for TB, since it generated some difficulties in access to healthcare.

Tuberculosis in Argentina is still an important public health issue; in 2019 there was a reported rate of 27.8/100,000 inhabitants, 6.4% higher than in 2018 (26.2/100,000 inhabitants). 78% of new cases were of pulmonary localization.⁴

Primary tuberculosis develops in patients who haven't been previously exposed; it is common in pediatric patients, and appears as a consolidation that affects the middle and lower lobes and adjacent lymph nodes. Lower lung field TB, as referred to in the reference studies, can be seen mainly in people living with HIV, diabetes, renal or liver disease, and those receiving corticoids and diagnosed with silicosis.⁵⁻⁷

This study was conducted for the purpose of describing the epidemiological and radiological characteristics of tuberculous pneumonia in patients without immunosuppression showing consolidation in the lower lung field.

MATERIALS AND METHODS

It is a retrospective (2017-2019 period) and prospective (2019-2021) study that analyzed TB cases treated at the Hospital General de Agudos Parmenio Piñero within said periods. The hospital is located in an area with high prevalence of tuberculosis (>100/100,000 inhabitants). The selection criteria for tuberculous pneumonia were: a) positive bacilloscopy in sputum or bronchoalveolar lavage, or diagnosis of TB with compatible epidemiology and clinical symptoms, b) not having comorbidities such as HIV, immunosuppression or addictions, c) not being underweight (BMI <18.5), d) chest X-ray with image of consolidation in lower fields.

The medical records of the patients included serological testing for HIV, hepatitis B and C and VDRL (Venereal Disease Research Laboratory) test, the TB diagnostic method performed and radiographic images.

Statistical analysis

Data obtained were analyzed with descriptive statistics tools. Chi Square test was used for qualitative variables (<https://www.socscistatistics.com>).

RESULTS

The analysis included 628 cases of pulmonary tuberculosis, 25 of which (4%) were diagnosed as lower lung field TB. 17 of those 25 cases (68%) were male. The mean age of patients was 33 ± 10 years. Most patients were Argentinian (56%), followed by Bolivians (24%), Peruvians (12%) and Paraguayans (8%). The proportion of females wasn't significant, compared to males. Table 1 describes the characteristics of patients being evaluated. There is predominance of right lower lobe involvement: 84%. Figures 1 to 4 show examples of the images found.

TABLE 1. Clinical characteristics of tuberculous pneumonia (n = 25)

Age: (years)	33 ± 10
Women	8 (32%)
Men	17 (68%)
BMI (kg/m²)	24.1 (19-30)
Nationality	
Argentinian	14 (56%)
Bolivian	6 (24%)
Peruvian	3 (12%)
Paraguayan	2 (8%)
Comorbidities	
None	22 (88%)
Renal lithiasis	1 (4%)
Vesicular lithiasis	1 (4%)
Gastritis	1 (4%)
Radiological description	
UNC, right base	21 (84%)
UNC, left base	4 (16%)
Diagnosis	
Empiric	4 (16%)
Direct	14 (56%)
Culture	5 (20%)
GeneXpert	2 (8%)

Radiological description: UNC: unilateral with no cave

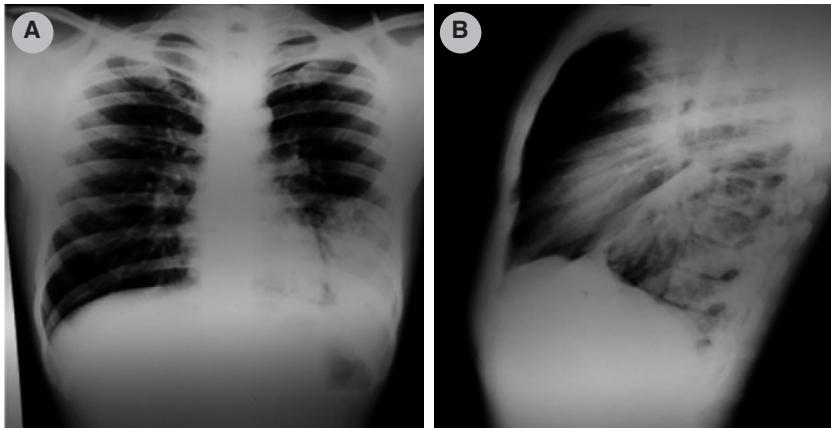


Figure 1. The anteroposterior (AP) and lateral chest X-ray of a 22-year-old man shows homogeneous consolidation at the left lower lobe.

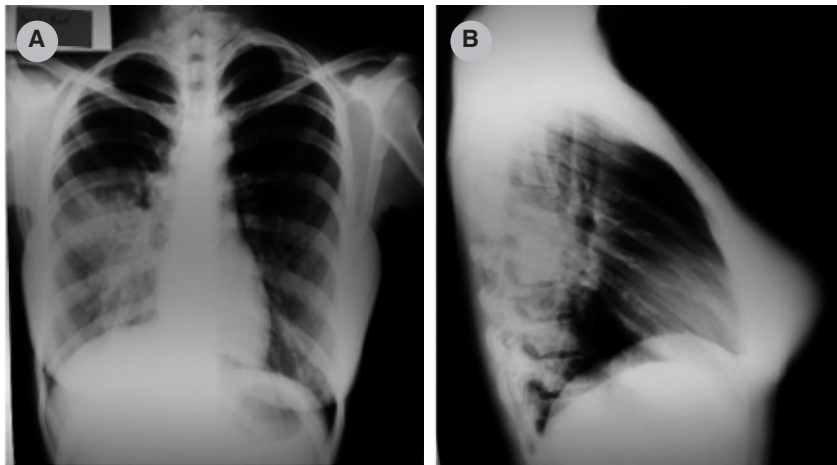


Figure 2. The anteroposterior (AP) and lateral chest X-ray of a 38-year-old woman shows homogeneous consolidation at the left lower lobe.

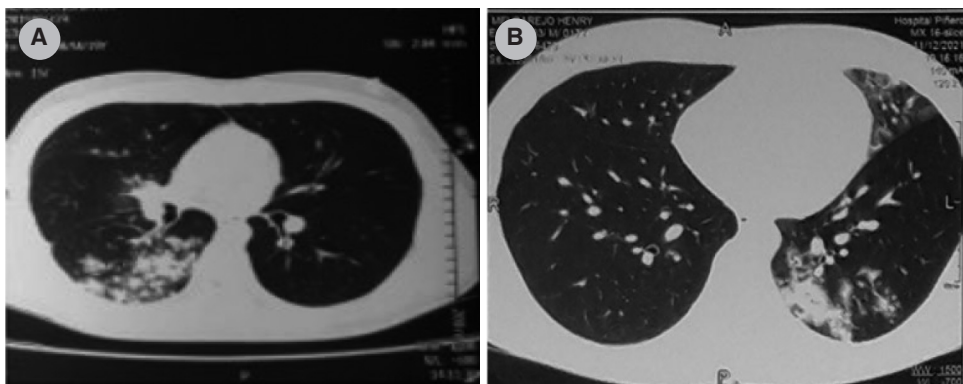


Figure 3. A) Axial tomography of the chest of a 29-year-old woman showing heterogeneous opacities at the superior segment of the right lower lobe. B) Axial tomography of the chest of a 47-year-old man showing heterogeneous opacities at the posterior segment of the left lower lobe.

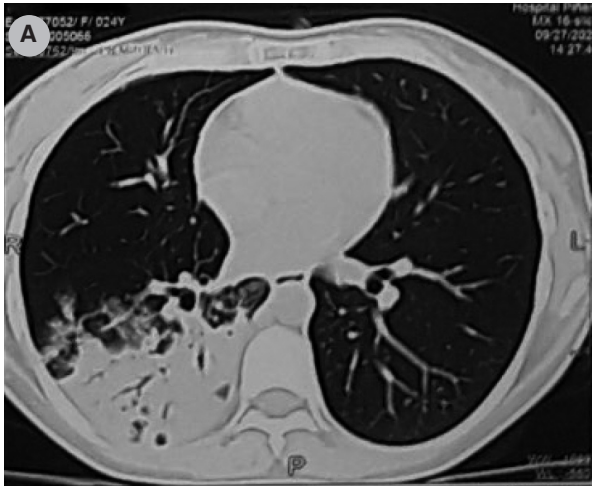


Figure 4. A) Axial tomography of the chest of a 23-year-old woman showing consolidation with air bronchogram at the superior segment of the right lower lobe.

DISCUSSION

In the group admitted to the study, we identified 4% of patients with lower lung field tuberculosis without associated comorbidities; there were no significant differences regarding sex; and involvement of the right lung base was predominant in the X-ray.

One of the published studies describing 62% predominance of women suggests the hypothesis that women have intercostal breathing with less diaphragmatic stretching that could result in less ventilation and less expansion of the lower lobes.⁸ In our case report we didn't find any differences relating to sex that support such hypothesis.

The observed predominance of the right lung base coincides with what was evidenced in previous studies.^{8,9} In the studies of India (61%) and Taiwan (64%), a predominance of the right lung base involvement was found that was close to the one found by us (84%). The hypothesis that was suggested for this finding is that the main right bronchus is anatomically shorter and has a sharper angle compared to the left bronchus, thus the infectious microorganisms more easily propagate towards the right lower lobe.⁸⁻¹⁰

Many authors have described that lower lung field TB occurs more frequently in specific groups of patients with diseases without immunosuppression.¹⁰⁻¹¹ In agreement with this, some studies in India found that tuberculous pneumonia is more frequent in: diabetes (29%), patients living with HIV (12%), patients receiving treatment with

corticosteroids (12%), with liver disease (11%), and with renal disease (5%). On the other hand, we couldn't find any published studies that describe this form of TB manifestation in groups of patients without comorbidities.⁸

Lower lung field TB is an atypical presentation of pulmonary TB. The radiographic image similarity with acute community-acquired pneumonia or even some types of bronchogenic adenocarcinomas entail diagnostic delays.¹² One of the proposed explanations is the transbronchial perforation of an affected hilar lymph node, with dissemination to the adjacent parenchyma.¹³

One limitation of this study is the lack of data identifying the exact time of diagnostic delay of the described group of patients. One strength is the fact of having shown that tuberculous pneumonia occurs even in patients without comorbidities considered as predisposing factors.

To conclude, tuberculosis must be included in the group of differential diagnoses of patients who show consolidation of the lower lung field and have a history of exposure or epidemiological risk, even if they don't have significant comorbidities or immunosuppression, thus avoiding diagnostic delay.

Conflict of interest

There is no conflict of interest.

REFERENCES

1. Global tuberculosis report 2020. <https://apps.who.int/iris/bitstream/handle/10665/336069/9789240013131-eng.pdf>
2. Organización Mundial de la Salud. Informe mundial de tuberculosis 2020. cms-decommissioning (who.int)
3. Ravigli M. The end TB strategy. World Health Organization. Disponible: <https://www.who.int/publications/i/item/WHO-HTM-TB-2015.19>. <https://bancos.salud.gob.ar/sites/default/files/2021-03/boletin-epidemiologico-tuberculosis-2021.pdf>
4. Boletín N° 4 Tuberculosis en la Argentina. 2021. Ministerio de Salud Argentina (marzo 2021). Disponible: <https://bancos.salud.gob.ar/sites/default/files/2021-03/boletin-epidemiologico-tuberculosis-2021.pdf>
5. Anton P, Jhon B, Elinor L. Manifestaciones clínicas y complicaciones de la tuberculosis pulmonar. 2021. Uptodate. (noviembre del 2021). Disponible en: https://www.uptodate.com/contents/clinical-manifestations-and-complications-of-pulmonary-tuberculosis?search=lower%20lung%20field%20tuberculosis§ionRank=1&usage_type=default&anchor=H17&source=machineLearning&selectedTitle=1~1&display_rank=1#H1
6. Castiñera A, López MR, Peña MJ, Liñares M. Manifestación radiológicas de la tuberculosis pulmonar. *Med Integral*. 2002;39:192-206.

7. Robert H, Fordham V, Elinor L. Epidemiología de la tuberculosis. Uptodate. 2021. Disponible en: <https://www.uptodate.com/contents/epidemiology-of-tuberculosis>
8. Singh SK, Tiwari KK. Clinicoradiological Profile of Lower Lung Field Tuberculosis Cases among Young Adult and Elderly People in a Teaching Hospital of Madhya Pradesh, India. *J Trop Med*. 2015;2015:230720. <https://doi.org/10.1155/2015/230720>
9. Lin CH, Chen TM, Chang CC, Tsai CH, Chai WH, Wen JH. Unilateral lower lung field opacities on chest radiography: a comparison of the clinical manifestations of tuberculosis and pneumonia. *Eur J Radiol*. 2012;81:e426-30. <https://doi.org/10.1016/j.ejrad.2011.03.028>
10. Gutierrez J, Zamudio S. Neumonía tuberculosa. Reporte de 20 casos y estudio caso control. *Acta Med Peru* 2011;18:5-11. <https://pesquisa.bvsalud.org/portal/resource/pt/lil-506725>
11. Ajai K, Saurabh S. Lower lung field pulmonary tuberculosis: An overview. *Indian Acad Clin Med*. 2015. Indian Acad Clin Med. Disponible: https://www.researchgate.net/publication/282282391_Lower_lung_field_pulmonary_tuberculosis_An_overview
12. Lee K, Choe H, Kim S. Clinical investigation of cavitary tuberculosis and tuberculous pneumonia. *Korean J Intern Med*. 2006;21:230-5. <https://doi.org/10.3904/kjim.2006.21.4.230>
13. González A, Fernández Cáceres M, Baldini M, Monteverde A. Tuberculosis pulmonar de campos inferiores. *Medicina (B. Aires)*