

# Leishmaniasis with Involvement of Upper and Lower Airways without Skin Lesions

**Correspondence:**

E-mail: marcoantoniogar@hotmail.com

Received: 07.29.2014

Accepted: 04.08.2015

**Author:** Marco Antonio García Choque

Bronchoscopy Service, Instituto Nacional de Tórax, La Paz - Bolivia

## Abstract

Mucocutaneous leishmaniasis is relatively frequent in the tropical regions of Bolivia. It coexists with another endemic disease of the region: tuberculosis. Tuberculosis frequently affects the upper airways, too. Leishmaniasis may be confused with tuberculosis, thus, its treatment can be erroneous. We report a case of leishmaniasis whose involvement profile is typical of tuberculosis.

**Key words:** mucocutaneous leishmaniasis, tropical ulcer, espundia

## Introduction

Twenty-one species of *Leishmania* have been identified as human pathogens. They are systematically divided into four complexes: Two New World *Leishmania* species complexes, the *L. mexicana* complex (also containing *L. amazonensis*) and the *L. braziliensis* complex (containing *L. panamensis* and *L. guyanensis*), and two Old World *Leishmania* complexes, the *L. principalis* complex (containing *L. tropica*) and the *L. donovani* complex (also containing *L. infantum*, also known as *L. chagasi*)<sup>16,17</sup>.

More than 12 million people worldwide are infected with leishmaniasis; 350 million people are at risk. Leishmaniasis is generally an endemic disease in 98 countries and regions; it is responsible for a burden of disease of 2.35 million disability-adjusted life years (DALYs), 2.3% of which occur in the Americas. 75% of all cutaneous leishmaniasis cases are estimated to be concentrated in 10 countries, four of which are in the Americas: Brazil, Colombia, Peru and Nicaragua. Fifteen out of 22 species of *Leishmania* causing disease in humans have been identified in the Americas, and 54 different species of vectors are potentially implicated in its transmission. In the Americas, an average of 60,000 cases of cutaneous and mucosal leishmaniasis and 4,000 cases of visceral leishmaniasis are diagnosed every year, with a 7% mortality rate (Fig. 1).

It is possible to certify that, up to this day, there are 4 parasitic species of leishmaniasis in Bolivia: *Leishmania (V) braziliensis*; *Leishmania (L) amazonensis*; *Leishmania (L) chagasi* and *L. (V) lainsoni*. The first species is an agent of mucocutaneous leishmaniasis (MCL); the second one is an agent of cutaneous *Leishmania* (CL) and diffuse cutaneous *Leishmania* (DCL). These two species clearly predominate in the national epidemiologic indices of the disease. The third species is an agent of visceral leishmaniasis (VL), and the fourth species produces rare cases of cutaneous leishmaniasis (CL). The third and fourth species generate sporadic clinical cases<sup>3,4</sup>.

In Latin America, 90% of mucocutaneous leishmaniasis occurs in Bolivia, Brazil and Peru, appearing as a complication in 5-20% of cutaneous leishmaniasis cases. It is generally produced by hematogenous dissemination of the parasite after a skin lesion, but may also disseminate by lymphatic route or direct extension of facial lesions. The mucosal involvement may be simultaneous with the skin lesion, or it may appear months, even decades after the occurrence of the primary lesion. The most frequently affected mucosa is the nasal mucosa, with septum involvement in up to 90% of the cases. Mucocutaneous leishmaniasis may also involve the palate, pharynx, larynx and upper lip. Palate lesions have a polypoid aspect. Laryngeal involvement consists in the presence of lesions of

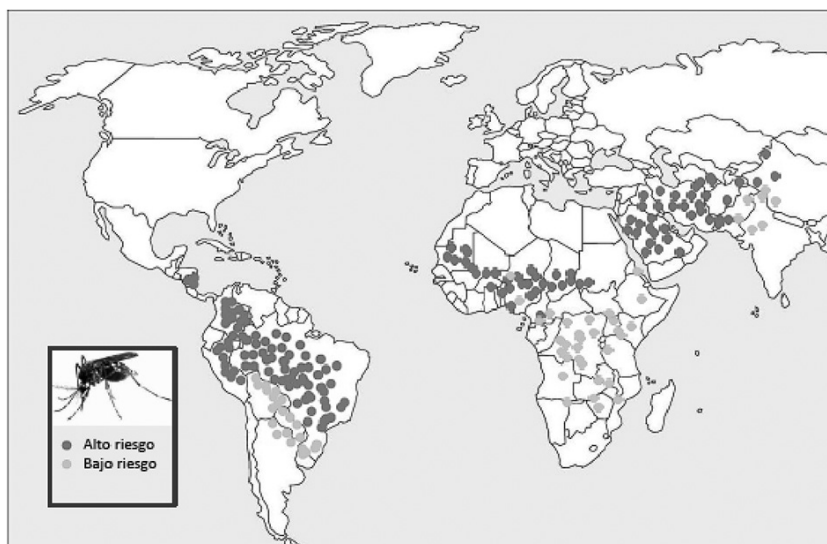


Figure 1. Worldwide distribution of leishmaniasis

a granulomatous aspect infiltrating the mucosa and vocal cords, which can lead to death from superinfection or obstruction.

Up to this day, more than 112 species of phlebotomus have been described in Bolivia, 5 of which are proven vectors of certain type of parasite.

In the Interandean Valley region (Yungas-La Paz), 2 out of the 17 antropophilic species that were found have an important role as vectors: *Lutzomyia longipalpis* (dominant species in peri-domestic settings), as a vector of *Leishmania* (*L*) *chagasi*, and *Lutzomyia nuneztovari anglesi* (dominant species in coffee plantations and remnant vegetation) with a role in the transmission of *L.* (*L*) *amazonensis* and *L.* (*V*) *braziliensis*<sup>9, 10</sup>.

In Bolivia, since ancient times, the disease has been related to one single population, los Yungas from La Paz Department. Nowadays, more cases are being reported among the Yungas “urban” populations (anthropization of the cycle). The new colonization regions, where important strategic development projects are being organized with mass population migrations, have spread the disease to 6 Departments (La Paz, Cochabamba, Santa Cruz, Beni, Pando, Tarija<sup>12</sup> (Fig. 2).

The worldwide prevalence of the disease is estimated to be 12 million cases throughout the world, with an incidence of 2 million new cases per year.

**Mucocutaneous leishmaniasis** has been first described in Bolivia by Dr. Manuel Antonio Vaca Diez in 1,876. It was studied for the first time during the Acre War, when many cases were observed

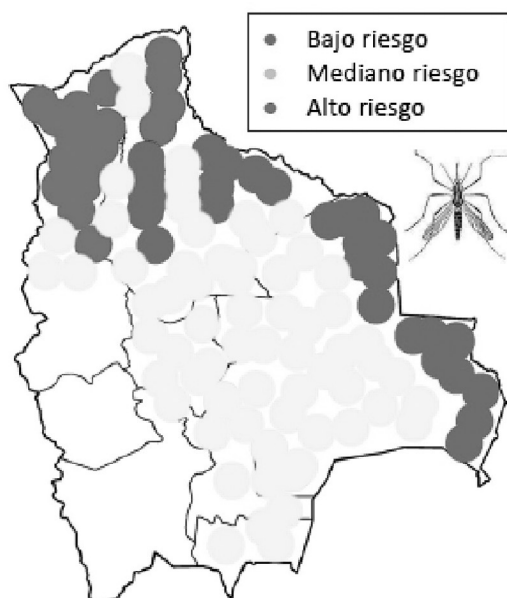


Figure 2. Risk level distribution

at the Mapiri River and the Colonial Territories. Elías Sagárnaga (1,904), Adolfo Flores (1,904), Arturo Ballivian Otero (1,905) and Jaime Mendoza (1,906) used the term ESPUNDIA to identify “tropical ulcers” of any origin. A few years later, Escomel (1,911) verified the presence of the amastigote parasite in certain patients with “espundia”, using this term to refer exclusively to American tegumentary leishmaniasis<sup>14-16</sup>.

Leishmaniasis is a zoonosis produced by *Leishmania* (*V*) *braziliensis* (Vianna 1,911). It has a

broad geographical distribution, from Central America to the north of Argentina, and is characterized by exacerbated cellular immunity that can be clinically translated to destructive and disfiguring mucocutaneous lesions of the oral and nasopharyngeal regions that appear lately after the primary ulcers have healed (access point for the parasite). These lesions show a granuloma consisting of macrophages and lymphocytes with very few parasites<sup>15</sup>.

The following is a case of mucocutaneous leishmaniasis affecting the area that goes from the upper airway to the tracheal bifurcation.

### Clinical Case

Male patient, 50 years old, born in Palca (Lowlands of Bolivia), who worked in a gold mine of a tropical region for 20 years, until 8 years ago. 2 years ago he came to this hospital (Instituto Nacional de Tórax-La Paz- Bolivia) because he had a productive cough and dysphonia. The laryngoscopic examination showed a partially amputated epiglottis and non-valuable valleculae; the glottic area was occupied by nodular lesions of granulomatous aspect. The diagnostic impression was laryngeal tuberculosis and “probable” leishmaniasis. The pathology report showed “specific chronic laryngitis”. The sputum smear test was negative. The patient was referred to the otolaryngology service of another hospital center, where he was finally diagnosed with “tuberculous laryngitis”, taking into account epidemiology, clinical examinations and another laryngoscopy. The patient began anti-tuberculous therapy but suspended it after a month due to gastric intolerance.

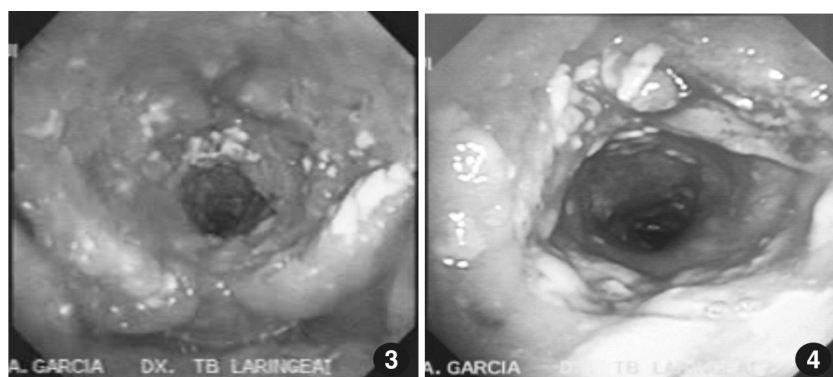
The patient decided not to receive medical care for a period of two years, after which he came to

this hospital again with chronic mucopurulent expectoration and dysphonia.

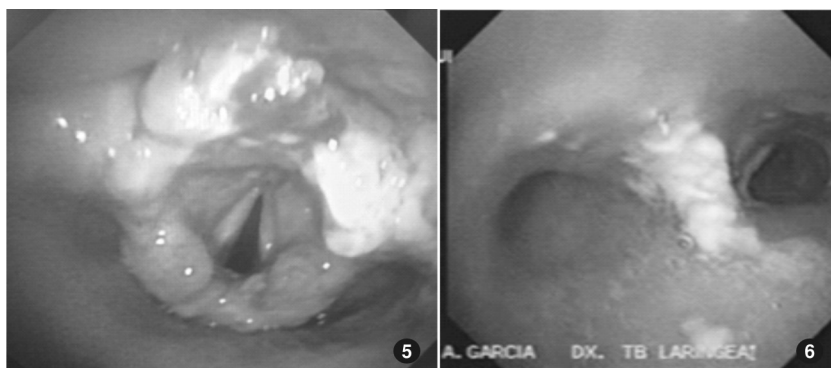
He had never shown any skin lesions. The physical examination showed rhonchus at both lung bases. Serologic tests for human immunodeficiency virus (HIV), the venereal disease research laboratory (VDRL) test, the purified protein derivative (PPD) test, the smear test, the acid-alcohol resistant bacilli (AARB) culture, the bacteriologic culture and a deep mycosis study of samples taken from laryngeal lesions and the bronchoalveolar lavage (BAL) analysis all came back negative. The chest X-ray showed paracardiac alveolar infiltrate and two-sided supradiaphragmatic infiltrate. The patient underwent a fibro-laryngo-tracheo-bronchoscopy that showed mucosal edema and multiple ulcers in both nostrils. The pharynx lost its morphological features and was turned into a narrow channel with granulomatous lesions, purulent discharge and fibrin stuck to the pharyngeal walls. The lesions ran from the pharynx to the trachea in its full extension.

The larynx showed partial amputation of the epiglottis and granulomatous lesions in its full extension. Vocal cords could only be identified with phonation. The subglottis and tracheal lumen showed 25% diameter reduction, with similar lesions. Lesions of a caseous aspect were observed next to the carina. The bronchial structure was preserved, but the primary left bronchus had an excessive amount of purulent discharge.

The histopathological report of a new lesion biopsy showed “non-specific chronic granulomatous inflammatory process.” The smear test of laryngeal and pharyngeal samples was negative. Scarification smear and Giemsa stain tests were negative. Serologic tests: The enzyme-linked immunosorbent assay (ELISA) for antileishmania



Figures 3 and 4. Laryngoscopy and bronchoscopy before starting treatment for leishmaniasis



**Figures 5 and 6.** Laryngoscopy and bronchoscopy 6 months after starting treatment for leishmaniasis

braziliensis antibodies had POSITIVE results. The Montenegro intradermoreaction (MIDR) test that was conducted 48 hours later showed an 8x11 mm reaction (positive MIDR).

After confirming the immunologic tests and the epidemiological record, it was decided to start treatment with meglumine antimoniate (Glucantime®) at a given dose of 20 mg/kg daily for 30 days. The patient showed improvement a week after initiation. Clinical examinations performed at the completion of treatment confirmed the favorable evolution of the symptoms, with an improvement of voice and respiratory distress. A new endoscopic control study conducted after 6 months showed that the epiglottis was still decapitated but less afflicted with edema and the vocal cords could be seen with preserved mobility. Tracheal and bronchial walls did not have lesions of a nodular aspect, but still showed pathological discharge<sup>19-25</sup>.

## Discussion

Leishmaniasis generally starts with the appearance of an ulcerated skin lesion at the parasite inoculation site and is less frequent with mucosal lesions caused by hematogenous dissemination. This case describes a patient from the Lowlands, an area endemic for tuberculosis, who worked at the Tropic, an area endemic for leishmaniasis but also with an epidemic of tuberculosis.

Although epidemiology and clinical examinations suggest the presence of mucocutaneous leishmaniasis, the final diagnosis is based on the identification of the parasite, which did not happen in this case. The scarification smear and Giemsa stain tests showed 75% sensitivity that decreased

as the condition evolved, reaching 20% after 6 months. Culture isolation and inoculation in hamsters showed 30% and 50% sensitivity, respectively. The negative results of the tests in this case could be explained by the time lapse between the onset of symptoms and the final diagnosis (more than 2 years). Polymerase chain reaction (PCR) is a highly sensitive molecular technique, very useful for mucosal lesions with few amastigote forms, but not easily available in most endemic areas. In this particular case, the germ was not identified, but the epidemiological and clinical diagnosis was confirmed by serologic tests and the Montenegro reaction. Actually, the diagnosis confirmation derived from the therapeutic response.

Leishmaniasis cases have been reported in different parts of the world, with oral mucosa involvement in almost every case. The World Health Organization (WHO) estimates that 2-3% of patients with acquired immune deficiency syndrome (AIDS) have developed leishmaniasis as an opportunistic infection. Mucosal leishmaniasis caused by *Leishmania braziliensis* is known to affect 1-10% of the cases.

Approximately 90% of patients present a prior cutaneous scar. Occasionally, mucosal lesions may also appear in patients with no previous skin lesions. The exclusive involvement of the mucosa is very rare<sup>20</sup>.

In the review published in 2003 by Aliaga et al, in 31 patients with mucosal leishmaniasis (42% with no underlying disease, 58% with other several medical conditions), the lesions were mostly located on the larynx (35%), oral mucosa (32%) and the nose (16%). Tracheal lesions were not described. Mucosal lesions were painless in all

patients, including this case. Ulcerations were reported in 6 patients. In a way similar to the biopsy results of our patient, according to the pathologic findings, the lesions showed chronic inflammatory infiltrate with granulomas.

Parasites are easily identified in smears of Giemsa stain or hematoxylin and eosin stain. But parasite growth in cultures occurs only in 60% of the patients<sup>1</sup>.

A recent review of related literature between 1950 and 2013 of the cases of patients with primary head-neck mucosal manifestations of leishmaniasis identified only 13 patients and showed that the most commonly affected sites were the larynx (54%), the mouth (31%) or the pharynx (23%) and endonasal site (15%), with the exophytic lesion as the most frequent clinical presentation (69%)<sup>18</sup>.

To the best of our knowledge, only four cases of tracheal leishmaniasis have been previously described in the literature, showing the exceptional nature of this case. Probably the delayed diagnosis (the case was initially interpreted as tuberculosis) justifies progression towards the lower airway, even without involvement of the immune system<sup>23-25</sup>.

The treatment of choice for every clinical manifestation of leishmaniasis is the administration of antimonial drugs such as meglumine antimoniate (Glucantime) and sodium stibogluconate (Pentostam). Meglumine is administered at a dose of 20 mg/kg of body weight/day via the intramuscular or intravenous route, to a maximum of 850 mg/day for at least 20 days. The possible adverse effects of these drugs are myalgia, joint pain, anorexia, nausea, vomiting, headache, hypertransaminasemia, chemical pancreatitis, thrombocytopenia and neutropenia. Patients with mucocutaneous leishmaniasis shall be treated with 20 mg of pentavalent antimony (0.2 ml of Pentostam) per kg of body weight daily, via the intramuscular or intravenous route during 30 days. An intralesional injection of sodium stibogluconate (0.5 to 1.0 ml) could be effective. It is a less expensive alternative with few side effects<sup>11-18</sup>.

We conclude that leishmaniasis is an endemic parasitosis with increasing incidence. This case stresses the importance to consider leishmaniasis as a differential diagnosis in patients with mucosal lesions, even without previous skin disease, since the primary lesion in some cases may go unnoticed. Despite its macroscopic similarities to tuberculosis,

leishmaniasis shall always be suspected in patients of endemic regions with mucosal lesions of the tracheobronchial tree.

**Conflicts of Interest:** the author declares there is no conflict of interest related to this publication.

## References

1. Aliaga L, Cobo F, Mediavilla JD et al. Localized mucosal leishmaniasis due to leishmania infantum: clinical and microbiologic findings in 31 patients. *Medicine (Baltimore)* 2003; 82(3): 147-58.
2. Angles R, Le Pont F, Desjeux P. Visceral canine leishmaniasis in Bolivia. *Trans R Soc Trop Med Hyg* 1982; 76, 704.
3. Balcazar JM. *Epidemiología en Bolivia*. La Paz: Ediciones Juventud, 1955.
4. Balcazar JM. *Historia de la medicina en Bolivia*. La Paz: Ediciones Juventud, 1956
5. Costa JW Jr, Milner DA Jr, Maguire JH. Mucocutaneous leishmaniasis in a us citizen. *Oral surgery, oral medicine, oral pathology, oral radiology, and endodontics* 2003; 96(5): 573-577.
6. Delgado O, Feliciangeli MM, Gómez B, Alvarado J, García L, Bello C. The re-emergence of American visceral leishmaniasis in an old focus in Venezuela: present situation of human and canine infections. *Parasite* 1998; 5(4): 317-323.
7. Desjeux P, Aranda E, Aliaga O, Mollinedo S. Human Visceral Leishmaniasis In Bolivia; First proven autochthonous case from los Yungas. *Trans R Soc Trop Med Hyg* 1983; 77(6): 851-852.
8. Martinez E, Le Pont F, Mollinedo S, Cupolillo E. A first case of cutaneous leishmaniasis due to *Leishmania (Viannia) lainsoni* in Bolivia *Trans R Soc Trop Med Hyg* 2001; 95 (4): 375-377.
9. Desjeux P, Mollinedo S, Le Pont F, Paredes A, Ugarte G. Cutaneous Leishmaniasis In Bolivia. A Study of 185 human cases from Alto Beni (La Paz Department) isolation and isoenzyme characterization of 26 strains of leishmania *brasilienis*. *Trans R Soc Trop Med Hyg* 1987; 81, 742-746.
10. Croft SL, Dye C, Kahl LP. Leishmaniasis: The first centenary (1885-1985) new strategies for control. *Parasitology Today* 1988; 4 (2): 51-53.
11. Faris RM, Jarallah JS, Khoja TA, Al-Yamani Mj. Intralesional treatment of cutaneous leishmaniasis with sodium stibogluconate antimony. *International Journal of Dermatology* 1993; 32(8): 610-612.
12. Forero M, Pérez A, Barajas NC, Leyva YA, Zamora C. Nasolaryngotracheal mucosal leishmaniasis in an Adolescent. *Arch Argent Pediatr* 2014; 112(3): E101-4.
13. Garret Aillon J. La espundia en Bolivia, observaciones del Dr. Manuel Antonio Vaca Diez. *Comentario histórico. Boletín Informativo de CENETROP* IX, 1-5, 1983.
14. Gatti G, Boggino J, Prieto C. Un nouveau foyer de leishmaniose viscerale en Amerique du sud. *Bulletin de la Societe de Pathologie Exotique* 1939; 67, 387- 395.
15. La Fuente C, Recacochea M, Tybayrenc M, Urjel R, Darras C, Cardozo L. Leishmaniasis en Bolivia: Presencia de dos complejos en los llanos orientales del departamento de Santa Cruz-Bolivia. *Boletín científico del CENETROP*, vol. XII, 1-15, 1986.

16. Le Pont F, Desjeux P. 1986; Leishmaniasis In Bolivia II. The involvement of *psychodopygus yucumensis* and *psychodopygus llanos martinsi* in the selvatic transmission cycle of *leishmania braziliensis* in a lowland subandean region; mem. Inst. Oswaldo Cruz, Rio de Janeiro, vol. 81(3): 311-318.
17. Le Pont F; Mollinedo S.; Mouchet J.; Desjeux P. Leishmaniose en Bolivie. IV. Le chien dans les cycles des leishmanioses en Bolivie. Rio de Janeiro: Inst. Oswaldo Cruz 1989, vol. 84 (3) pp 417-421.
18. *Leishmania* species of all major complexes may be responsible for ml over the world. World health organization, "world health organization working to overcome the global impact of neglected tropical disease," first who report on neglected disease, World Health Organization, Geneva, Switzerland, 2010.
19. Marshall BG, Kropf P, Murray K et al. Bronchopulmonary and mediastinal leishmaniasis: an unusual clinical presentation of *Leishmania donovani* infection. *Clin Infect Dis* 2000; 30(5): 764-9.
20. Mignogna MD, Celentano A, Leuci S et al. Mucosal leishmaniasis with primary oral involvement: a case series and a review of the literature. *Oral Dis* 2015; 21(1): e70-8.
21. Mollinedo S, Muñoz M, Hervas D et al. Leishmaniasis visceral y tegumentaria en niños en dos zonas endémicas de Bolivia. *Parasitología al día* 1992; 16: 11-120.
22. Murray HW, Berman JD, Davies CR, Saravia NG. Advances in Leishmaniasis. *The Lancet* 2005; 366(9496): 1561-1577.
23. Piens MA, Arpin D, Rabodonirina M, Loire R, Brune J. Tracheal stenosis of inflammatory aspect. *Rev Pneumol Clin* 1997; 53(3): 150-2.
24. Valda I. Leishmaniasis cutáneo difusa: informe del segundo caso boliviano; Cuadernos del Hospital de Clínicas 1980; 31,1.
25. Viglianesi A, Di Mauro D, Petrillo G. Multidetector computed tomography aspects of tracheal mucosal leishmaniasis localization *Jpn J Radiol* 2011;29(1): 59-62.